

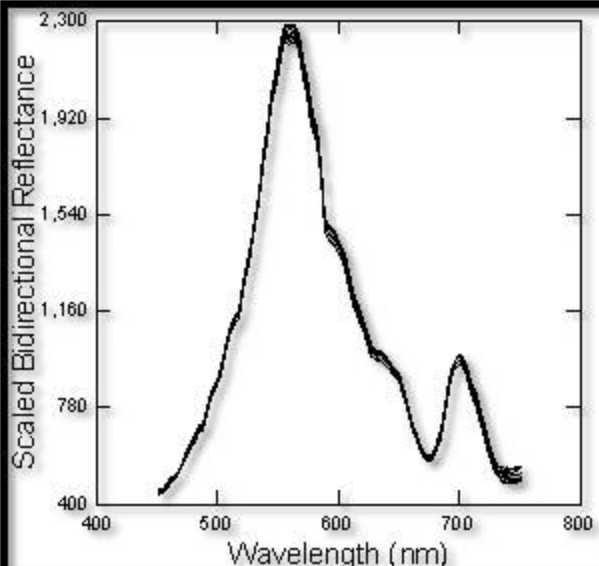


Selected pixel water reflectance in **Northern Indian River Lagoon, Florida** indicating the presence of very high chlorophyll (algal biomass). 10 Pixels from a uniform water region. The Lower part of the hyperspectral 3 Band airborne image (684, 530, 489 nm) shows the submerged vegetative habitat. GSD pixel size is ~0.5 meters. A false color image is shown.

Data collected by C. Bostater, June 2010 at 1,500 feet using the custom *HSI pushbroom camera system developed by Dr. Bostater*. See the following papers for sensor and aircraft instrument specifications:

Bostater, C., Jones, J., Frystacky, H., Kovacs, M., 2010, Integration, Testing, and Calibration of Imaging Systems for Land and Water Remote Sensing”, SPIE Vol. 7825, pp. 199-215.

Bostater, C., 2012, Airborne Multisensor Remote Sensing Systems for Subsurface Feature Detection in Littoral Zones, SPIE, Vol. 8532, pp. 853208-1 to 13.



#### Acquisition Systems Metafile Description:

- Mapping Camera, 12 inch Cone, aft (9 inch AGFA Aviphot X400 PE1 Color Negative Film Scanned: 3 Band Multispectral imagery, ~5-7 cm scale pixels (~475 mega pixel images).
- 2 Full HD Video Digital Cameras, DGPS encoding (forward & aft), GZ-HM550.
- Nikon D2Xs 12.3 Digital Frame Camera, DGPS encoded, Telephoto Lens & Vibration Reduction, cm scale pixels.
- Hyperspectral Digital Pushbroom Imaging System, KB-HSI-A-SHARK-Fusion System 64-1024 spectral channels; 1376 spatial pixels, ~39° FOV Lens, V8E ImSpector transmission spectrograph; TE temperature cooled camera @ -21°C with real time data, signatures, and image display; GPS and IMU data displayed
- DGPS: Garmin 196@1 Hz; Two HICOM 406BT@1 Hz; Garmin DGPS 496@5 Hz
- IMU: Motion Node USB @ 100 Hz
- 400B Autopilot in Heading Mode (Yaw, Pitch & Roll Platform stabilization)
- Gimbal Mounted KB-HSI-A-SHARK-Fusion System Pushbroom Imaging System & IMU
- Fujitsu Pen Tablet ST5012/ST6012 Airborne Data Recording & Acquisition

Note: The HSI Custom Platform System hardware, software development and gimbal system Developed by Dr. Charles Bostater, 2004-2009.